



## **Jeff Donovan MD PhD FRCPC**

*Dermatologist, specializing in hair loss*

750 West Broadway Suite 905 - Vancouver BC V5Z 1H8

Phone: 604.283.9299 Fax: 604.648.9003

Email: [vancouveroffice@donovanmedical.com](mailto:vancouveroffice@donovanmedical.com) Web: [www.donovanmedical.com](http://www.donovanmedical.com)

### **Seborrheic dermatitis**

#### **What is SEBORRHEIC DERMATITIS?**

- This is a common condition which affects 1-3 % of individuals.
- It causes redness and scaling and flaking in the scalp and sometimes the eyebrows forehead and nose area as well.
- 'Dandruff' is a very mild variant with lots of flaking but not much redness.
- It is common and worsens in winter. It can be worsened by diet and emotional stress

#### **What is the cause of SEBORRHEIC DERMATITIS?**

- A yeast known as *Malassezia globosa* is the cause of seborrheic dermatitis
- Alcohol, diet, changes in humidity and stress can worsen these conditions
- Tell Dr. Donovan if you take medications, as some can flare or induce seborrheic dermatitis. These medications include auranofin, aurothioglucose, buspirone, chlorpromazine, cimetidine, ethionamide, gold, griseofulvin, haloperidol, interferon alfa, lithium, methoxsalen, methyldopa, phenothiazines, psoralens, stanozolol, thiothixene, and trioxsalen

#### **How is the diagnosis made?**

- Dr. Donovan will recognize the features of seborrheic dermatitis
- There is often redness and scaling along the frontal hairline
- Itching is sometime present and excoriated areas may be present
- Beard, eyelashes, eyebrows and moustache may be affected
- The hair may appear dirty/greasy and have an odour

## How is SEBORRHEIC DERMATITIS treated?

Dr. Donovan will advise how he or she wishes you to use the treatment.

One or more of the following may be prescribed:

- a) Shampoos. Used on the scalp 2-3 times per week for 4 weeks and then weekly
  - Zinc pyrithione shampoos
  - Ketoconazole shampoos
  - Ciclopirox shampoos
  - Selenium sulfide shampoos
- b) Topical steroids
- c) Topical retinoids

The most important thing to remember about treatment is that seborrheic dermatitis can be a 'chronic' condition and the following treatments may be needed periodically for many years.

## DR. DONOVAN – ARTICLES ON SEBORRHEIC DERMATITIS

### ARTICLE 1: Flares of seborrheic dermatitis common in winter

Seborrheic dermatitis (SD) is a close cousin of 'dandruff' and is due to a yeast known as Malassezia that is extremely common in the scalp.

#### Triggers of SD

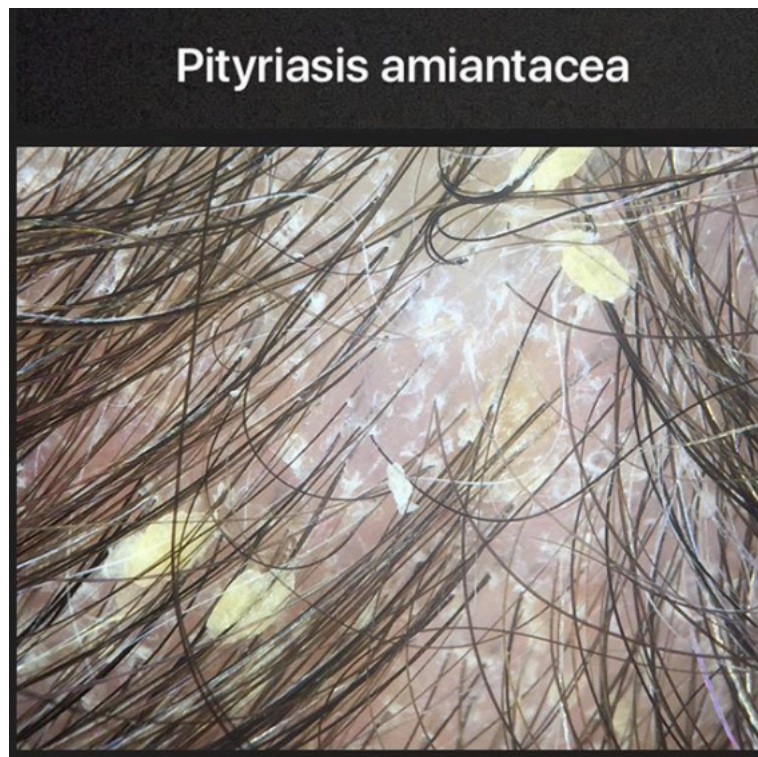
There are many triggers of SD 'flares' including stress, dry and cold weather, certain medications.

Flares of seborrheic dermatitis are very common in winter. For 5 % of individuals who experience seborrheic dermatitis and the occasional scalp dryness, itchiness and redness that accompanies the condition, the winter months can be problematic.

### **Treatments for SD**

I advise the vast majority of my patients to reach for shampoos containing zinc pyrithione (i.e. Head & Shoulders), selenium sulphide (Selsun Blue), ketoconazole (Nizoral), or ciclopirox (prescription Stieprox) at least once per week in the winter months. There are many myths surrounding these shampoos and they are undoubtedly one of the best kept secrets for great hair.

## **ARTICLE 2: PITYRIASIS AMIANTACEA**



Pityriasis amiantacea is not a diagnosis. Rather it is a phenomenon that sometimes happens to the skin and hairs during the process of inflammation.


The finding of pityriasis amiantacea is often seen in patients with psoriasis,

seborrheic dermatitis and various eczemas.

The photo to the right is a magnified photo of the scalp of a patient with "pityriasis amiantacea" from psoriasis.

Treatment includes identifying the root cause. Treatment such as topical steroids, steroid injections, anti dandruff shampoos, salicylic acid, tar all play a role in treatment.

## ARTICLE 3: SEBORRHEIC DERMATITIS AND BIOTIN: IS THERE A ROLE?



Seborrheic dermatitis is a flaky, red condition often affecting the scalp, eyebrows and folds of adults. Children have a form known as "cradle cap" and some have a severe form affecting their entire body.

It is well known that infants with biotinidase deficiency as well as other inborn errors of metabolism can have seborrheic dermatitis-like rash on the body. For children with biotinidase deficiency, rapid administration of biotin is life saving. Many countries now screen for biotinidase activity at birth. About 1 in 61,000

newborns have biotinidase deficiency.

But what about the use of biotin in seborrheic dermatitis ?

A very interesting study dating back to 1975 looked at the use of biotin in 25 infants with generalized seborrheic dermatitis. One group received IV biotin infused slowly, one group had IV biotin infused rapidly, one had IV biotin and B vitamins, and one had IV biotin with antibiotics. What were the surprisingly results? Well, all had improvement in seborrheic dermatitis - even in those with normal serum and urinary biotin levels.

However, just the next year, in 1976,, Keipert published another study showing the oral biotin did not in fact help infants with seborrheic dermatitis.

Conclusion

I truly believe that the jury is still out on the role of biotin in seborrheic dermatitis not only in newborns and infants but also in adults. More good studies are needed and we're conducting few studies are present with high dose front end loading of biotin in seborrheic dermatitis.

#### **Reference**

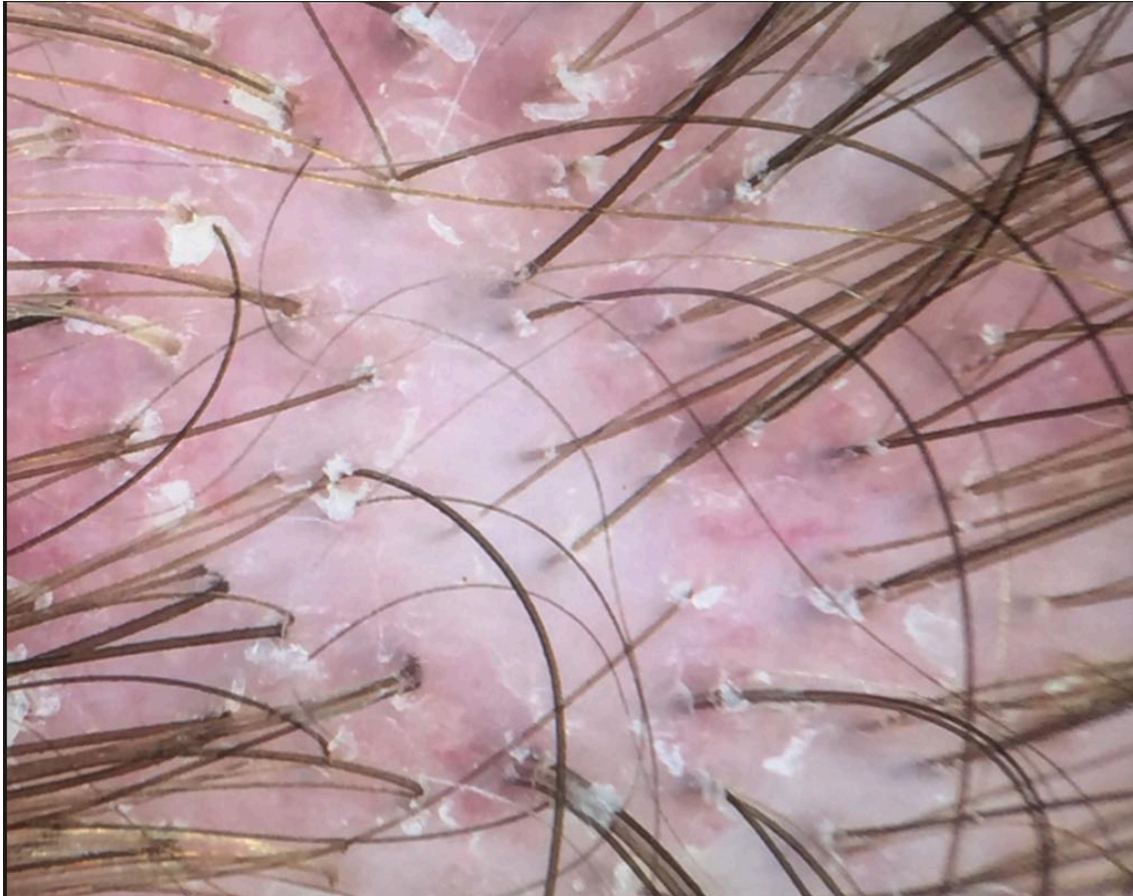Arch Dis Child. 1975 Nov; 50(11): 871–874. Generalized seborrhoeic dermatitis. Clinical and therapeutic data of 25 patients.

J Messaritakis, C Kattamis, C Karabula, and N Matsaniotis

2. Oral use of biotin in seborrhoeic dermatitis of infancy: a controlled trial. Clinical Trial. Keipert JA. Med J Aust. 1976.



## Article 4: SEBORRHEIC DERMATITIS AND SCARRING: SEBORRHEIC FOLLICULITIS



Can a seborrheic dermatitis lead to a scarring alopecia-like phenomenon?

In 2015, Australian researchers reported an interesting article in the Australasian Journal of Dermatology suggesting the possibility of a low grade folliculitis which ultimately leads to development of a scarring alopecia. They termed the condition "seborrheic folliculitis."

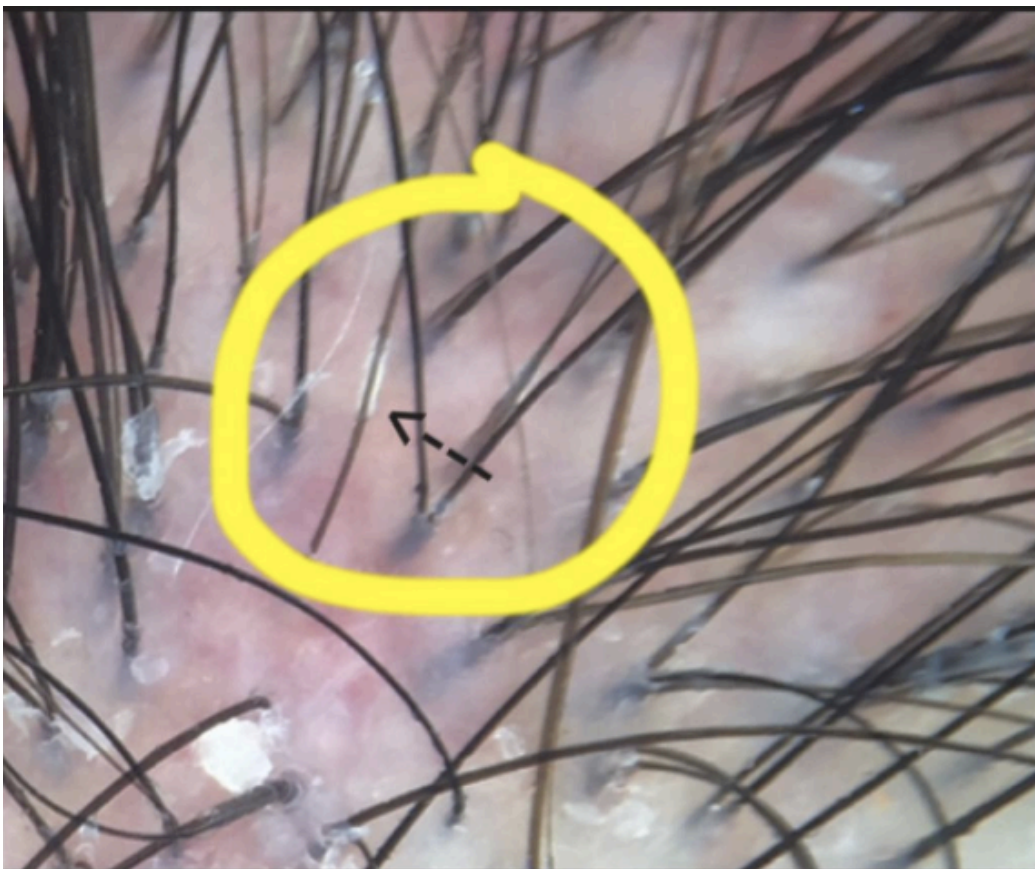
Here is one such example of a "seborrheic folliculitis" in a patient with androgenetic alopecia. Scarring is present and focal areas devoid of hair can be found on the scalp.

### Reference

Pitney et al. Is seborrheic dermatitis associated with a diffuse, low-grade folliculitis and progressive cicatricial alopecia? . Australas J Dermatol. 2015

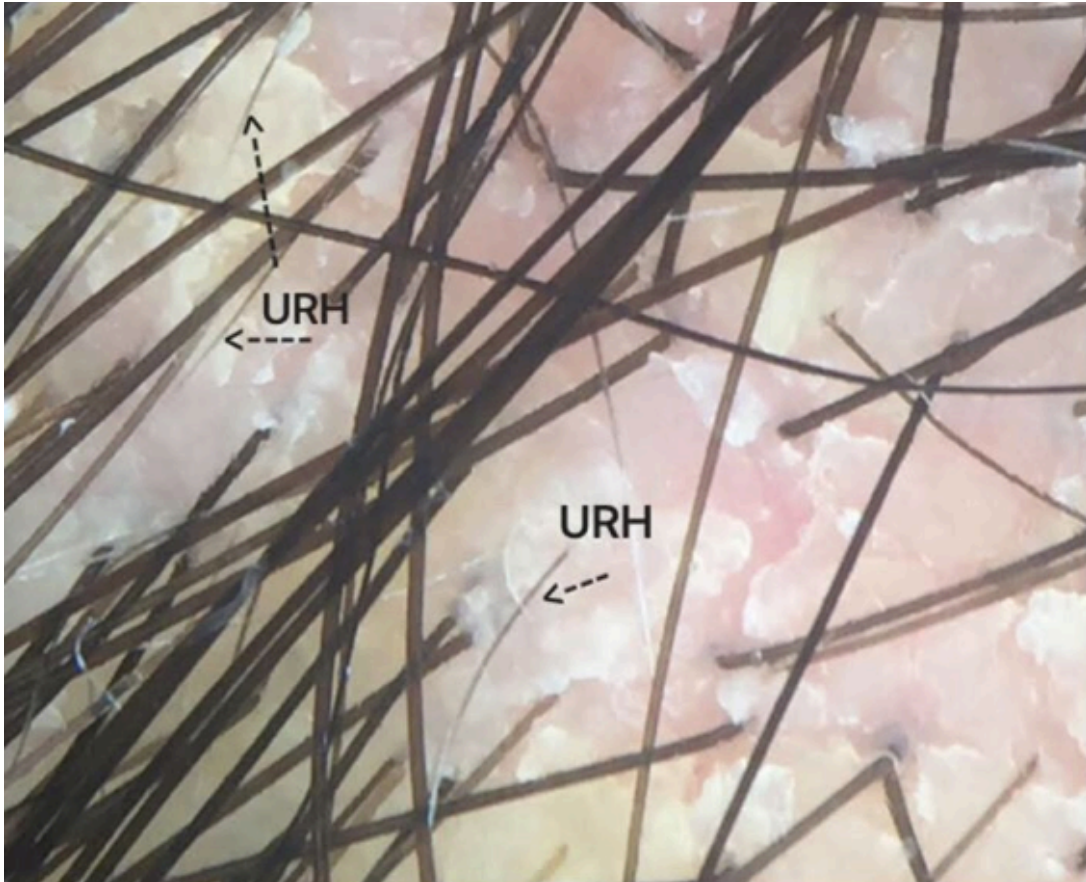
## ARTICLE 5: HAIR CASTS

Hair casts are cylindrical (tubular) material that sometimes surround hair follicles. Hair casts are said to be "primary" in nature when not associated with an underlying scalp disorder and "secondary" when associated with an underlying disorder. Many inflammatory conditions can be associated with hair casts including seborrheic dermatitis, psoriasis, pityriasis amiantacea, traction ... and others. The patient in this photo has hair casts from seborrheic dermatitis.



## ARTICLE 6: IS IT POSSIBLE FOR SEB DERM TO CAUSE HAIR LOSS?

May 23, 2017



Seborrheic dermatitis and the closely related condition "dandruff" are two scaly scalp conditions that are common in the general population. I'm often asked if these conditions can cause hair loss. It is a fact (not a speculation) that seborrheic dermatitis can cause an individual to experience increased hair shedding (telogen effluvium). This has been shown many times in various studies.

Dr Pierard- Franchimont and colleagues have done very interesting research in the area of seborrheic dermatitis and dandruff. They showed about 10 years ago that the more seborrheic dermatitis a person has, the more shedding (telogen effluvium) a person will experience. This is important information to know because it tells us that individuals with severe seborrheic dermatitis are likely to have a severe telogen effluvium. Dr Pierard Franchimont and others have also shown data that the inflammatory reaction can even accelerate male balding in some cases making it important to aggressively treat seborrheic dermatitis in patients with hair loss.



There is no doubt about the relationship between seborrheic dermatitis and shedding. Companies that manufacture dandruff shampoos study shedding patterns to determine if their shampoo is working. Anti-dandruff shampoos can reduce shedding.

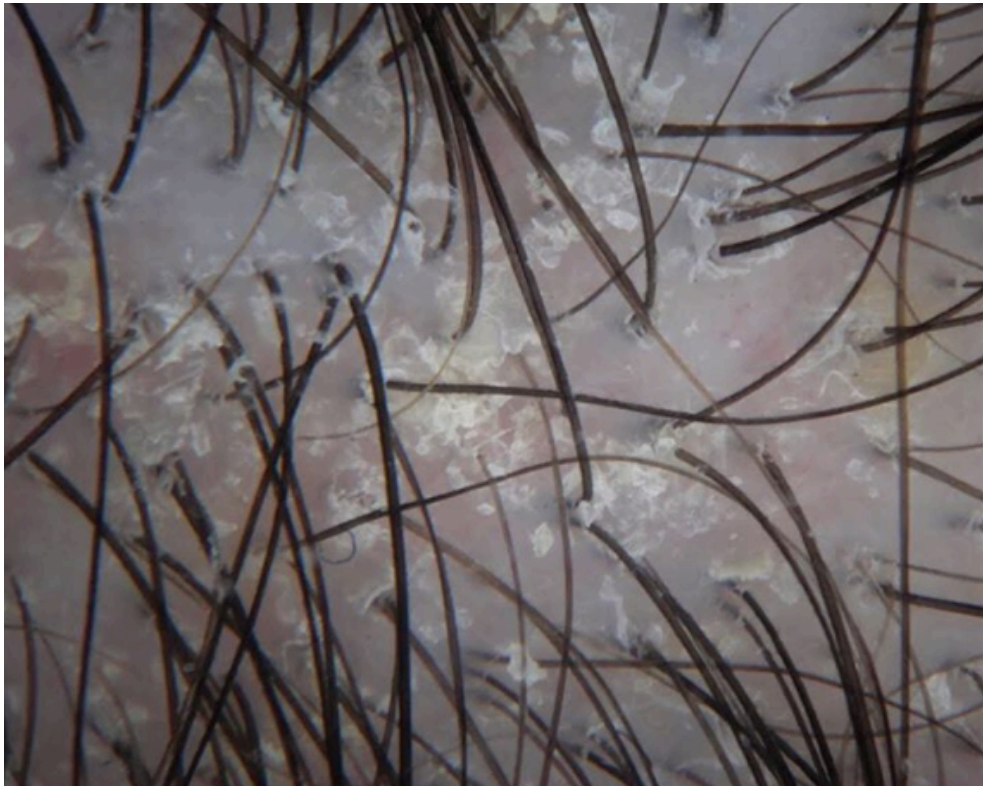
In summary, seborrheic dermatitis can certainly cause a telogen effluvium. This photo shows the scalp of a patient with moderate seborrheic dermatitis.

Numerous upright regrowing hairs (URH) are seen, which is a typical sign of a hair cycling abnormality (telogen effluvium).

#### Reference

Dandruff-associated smouldering alopecia: a chronobiological assessment over 5 years. Piérard-Franchimont C, et al. Clin Exp Dermatol. 2006

## ARTICLE 6: SEBORRHEIC DERMATITIS & DANDRUFF



A fungus known as "Malassezia" is now believed to play a key role in seborrheic dermatitis and dandruff.

Most human beings are covered in Malassezia. It's just part of being human and

living on planet Earth. Only in a minority of people do these fungi cause any sort of health problems.

Malassezia were originally discovered by the French scientist Louis Charles Malassez in the late 1800's. There are now recognized to be 14 types of Malassezia. For trivia lovers, *Malassezia globosa* (mainly) and *Malassezia restricta* (less so) are the most common causes of seborrheic dermatitis. Malassezia are difficult to culture so one can not simply send samples off to the lab. These fungi need fats and lipids to survive - so they live in areas of the body rich in sebaceous (oil) glands such as the scalp and face.

Anti-dandruff shampoos are generally quite effective in killing these fungi. Common ingredients in shampoos include ketoconazole, zinc pyrithione, selenium sulphide and ciclopirox.

