

## Effective Treatment of Folliculitis Decalvans: Azithromycin in Monotherapy

Andre MC\* and Soares RO

Centro de Dermatologia, Cuf Descobertas Hospital, Lisbon, Portugal

### Abstract

**Background:** Folliculitis Decalvans is a neutrophilic inflammation of the scalp characterized by painful recurrent purulent follicular exudation resulting in primary cicatricial alopecia. Etiology is unclear but infection may play a role. Systemic antimicrobial agents, namely tetracyclines, are useful to control the disease.

**Objective:** The authors present a case series of 19 patients treated with oral azithromycin. Conclusions: Most of the patients improved and no important side effects were reported.

**Keywords:** Folliculitis decalvans; Follicular exudation; Cicatricial alopecia

### Introduction

Folliculitis Decalvans (FD) is a rare neutrophilic inflammation of the scalp characterized by painful recurrent purulent follicular exudation resulting in primary cicatricial alopecia. Although it is not an infection, bacterial superantigens may trigger inflammation [1] and antimicrobials, namely tetracyclines, have been tried previously with good results [2-8] and are often the first therapeutic approach.

There are also anecdotal improvements reported with isotretinoin, dapson, adalimumab and infliximab, topical tacrolimus, ndYag-LASER and photodynamic therapy [6,9-16]. Most of our FD patients are treated with minocycline. However, in south European countries tetracycline is avoided from May to October due to its hyperpigmentation potential. Thus, an antimicrobial drug effective in FD but without photosensibilization potential would be optimal. The beneficial effect of azithromycin in acne is well known [17-21], used both in monotherapy [17-19] and in combination with isotretinoin [20,21]. The authors present a case series of 19 patients with FD treated successfully with azithromycin in monotherapy.

### Material and Methods

**Inclusion:** Patients presenting to our hair clinic from 01/01/10 to 31/12/12 with first diagnosis of active Folliculitis Decalvans (FD). Active FD was defined clinically: inflammatory perifollicular papules, papulo-crusts and pustules in Figure 1 and by dermoscopy: follicular tufts, perifollicular erythema, crusts and pustules.

Patients with residual FD lesions of residual cicatricial alopecia (Figure 2) were excluded.

A detailed clinical history followed by a thorough scalp examination and routine systemic examination were performed. The severity of the disease was assessed based on objective and subjective criteria. Objective criteria: the total number of papules, papulo-crusts and pustules on the scalp. Subjective criteria: global score 0-6 based in addition of partial score regarded to pruritus (0-2), burn sensation (0-2) and pain (0-2).

Patients with previous medication waited six months after stopping it before being enrolled. The patients were prescribed with azithromycin 500mg/day for 3 consecutive days every 2 weeks.

The severity of the disease was assessed before treatment and after 1, 3 and 6 months. Primary end point was the change in the number of lesions and secondary end point the change in subjective global score.

T-student test was used for statistical analysis.

### Results

There were 15 males and 4 females, with 18 to 59 years of age, with a mean age of 27 years old. The course of the disease varied from 5 weeks to 17 months. Common complaints were pain (10 patients), burn sensation (8 patients), pruritus (3 patients) and hair loss (6 patients). Familial history of the disease was found in 3 patients. Vertex involvement was seen in 12 patients and occipital involvement in 9. Three patients had papules or pustules all over the scalp. Papular or pustular lesions were observed in all patients and areas of cicatricial alopecia in 11 patients. Tufted hairs (clinically or dermoscopy) were present in 18 patients. Table 1 refer to clinical data of the patients and Table 2 to the number of papular, papulo-crust and pustular lesions (Figure 3) over time, respectively. The change in this number over time is showed in Figure 4 and the change in subjective global score (0-6) obtained by addition of partial scores of pruritus (0-2), pain (0-2) and burn sensation (0-2) in Figure 5.

### Discussion

Our group of patients has a male predominance observed in other studies as well. In patients with FD minocycline is our first choice, usually in monotherapy. In some non-responsive patients we associated rifampicin or clarithromycin. The main reason for the study is that minocycline use is associated with hyperpigmentation [22,23]

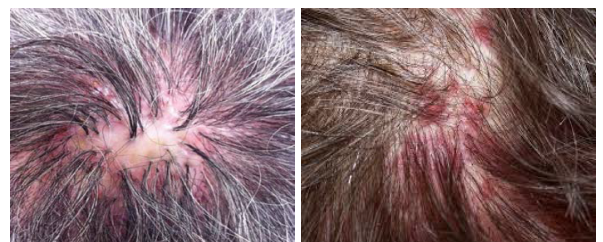

Figure 1: Inclusion: active FD: papules, papulo-crust or pustular lesions.

\*Corresponding author: Dr. Andre MC, Centro de Dermatologia, Cuf Descobertas Hospital, Lisbon, Portugal, Tel: +351 210 025 200; E-mail: [marisa.c.andre@gmail.com](mailto:marisa.c.andre@gmail.com)

Received November 19, 2014; Accepted March 04, 2015; Published March 07, 2015

**Citation:** Andre MC, Soares RO (2015) Effective Treatment of Folliculitis Decalvans: Azithromycin in Monotherapy. Hair Ther Transplant 5: 131. doi: 10.4172/2167-0951.1000131

**Copyright:** © 2015 Andre MC, et al. This is an open-access article distributed under the terms of the Creative Commons Attribution License, which permits unrestricted use, distribution, and reproduction in any medium, provided the original author and source are credited.

Sex	age	Family history	Course (weeks)	Pain	Burn Sens.	pruritus	alopecia	Vertex Inv.	Occipital Inv.	Tufted
M	24		8	x		x	x	x		x
M	19		6		x			x		x
M	19	x	18		x		x	x		x
M	38		68	x			x	x		x
F	26		43			x			x	x
M	25		8		x		x	x		x
M	23	x	9	x				x		x
M	31		5	x					x	x
M	59		12		x		x		x	x
F	18		7	x			x	x	x	x
M	23		8	x				x		
F	26		12		x		x	x		x
F	22		8	x		x			x	x
M	19		9				x	x		x
M	47		11		x				x	x
M	20		12	x			x	x	x	x
M	27	x	12		x		x		x	x
M	30		16	x	x			x		x
M	21		9	x			x		x	x

Table 1: Clinical data of the patients.

sex	age	Inicial number Papulae/pustulae	Number papulae/pustulae 1 month	Number papulae/pustulae 3 month	Number papulae/pustulae 6 month
M	24	5	2	0	0
M	19	8	3	1	0
M	19	3	1	0	0
M	38	11	6	2	1
F	26	8	2	0	0
M	25	8	3	0	0
M	23	7	4	1	0
M	31	11	3	2	2
M	59	10	2	1	1
F	18	4	0	0	0
M	23	7	2	0	0
F	26	8	3	0	0
F	22	6	1	0	0
M	19	9	4	2	2
M	47	7	2	0	0
M	20	10	3	1	0
M	27	17	4	2	2
M	30	6	0	0	0
M	21	9	3	0	0

Table 2: Papular and pustular lesions over time.

and this adverse effect may limit its use during summertime. Due to this fact, often, we stop the drug from may to october, with concomitant worsening of FD in the majority of patients.

The primary end point of our study with azythromycin was the change in total number of papules, papulo-crusts and pustules and it has been chosen for being a very exact and measurable criteria. The level of inflammation and the progression to areas of cicatricial alopecia are more important clinical criteria but more difficult to measure with accuracy. In our FD patients azithromycin was clearly able to reduce the total number of lesions. The differences between initial number and lesions and post-treatment number of lesions are highly significant and cannot be justified by fluctuation in disease activity (if we consider that in a population of FD patients this number will not decrease over time, we have a *t student*  $p < 0.0001$ ).

The clear reduction in subjective global score (secondary endpoint) reveals that azithromycin is able to improve symptoms (pruritus, pain, burn sensation).

Probably, this action may be due both to antiinflammatory [24-26] and antimicrobial [27] properties of azithromycin (a recent study showed lower resistance of *Propionibacterium acnes* to this drug than to clindamycin, erythromycin, oxytetracycline, or doxycycline).

Several oral antibiotics whether used in monotherapy or in association showed some effectiveness in FD patients. Relapses are frequently observed after discontinuation of the antibiotic and patients might have to stay on low dose antibiotics for quite some time. Rifampicin at a dose of 300 mg bid 10-12 weeks is known to be a good antistaphylococcal agent and eliminating long-term carriers. Nowadays it is recommended to use rifampicin in combination with

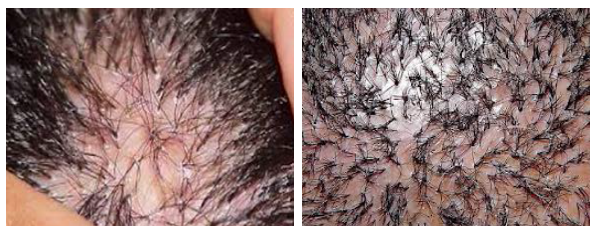

Figure 2: Exclusion: non-active FD: cicatricial alopecia.

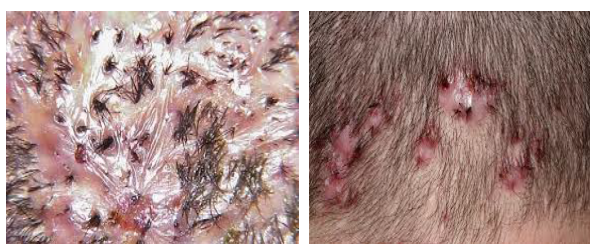

Figure 3: Disease activity measured by number of papules, papulo-crust or pustular lesions.

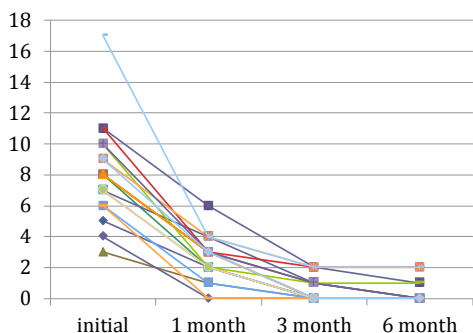


Figure 4: Number of papules, papulo-crusts and pustules over time.

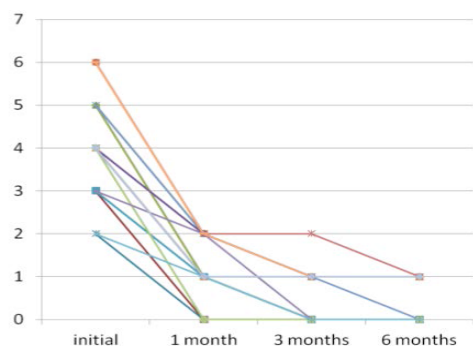


Figure 5: Subjective activity index (0-6) (pruritus 0-2, burn sensation 0-2, pain 0-2).

clindamycin to avoid emergence of resistance and in order to achieve high intracellular concentration which results in a potential to eradicate *S. aureus* [28] However, this therapeutical association might cause a higher incidence of adverse effects, a reason why azithromycin should be considered to be a valid treatment choice.

No patient complaint of adverse effects with this treatment.

In our opinion, this benefic action in FD course may turn this drug a good candidate for minocycline substitution during summertime in countries in which sun expose may induce minocycline hyperpigmentation.

## References

- Powell JJ, Dawber RPR, Gatter K (1999) Folliculitis decalvans including tufted folliculitis: Clinical, histological and therapeutic findings. *Br J Dermatol* 140: 328-333.
- Whiting DA (2001) Cicatricial alopecia: Clinico-pathological findings and treatment. *Clin Dermatol* 19: 211-215.
- Annessi G (1998) Tufted folliculitis of the scalp: A distinctive clinicohistological variant of folliculitis decalvans. *Br J Dermatol* 138: 799-805.
- Chandrawansa PH, Giam Y (2003) Folliculitis decalvans - a retrospective study in a tertiary referred center, over five years. *Singapore Med J* 44: 84-87.
- Abeck D, Korting HC, Braun-Falco O (1992) Folliculitis decalvans: Long-lasting response to combined therapy with fusidic acid and zinc. *Acta Derm Venereol* 72: 143-145.
- Gemmeke A, Wollina U (2006) Folliculitis decalvans of the scalp: response to triple therapy with isotretinoin, clindamycin, and prednisolone. *Acta Dermatovenerol Alp Panonica Adriat* 15: 184-186.
- Kaur S, Kanwar AJ (2002) Folliculitis decalvans: Successful treatment with a combination of rifampicin and topical mupirocin. *J Dermatol* 29: 180-181.
- Brozina SJ, Cohen LE, Fenske NA (1988) Folliculitis decalvans--response to rifampin 42: 512-515.
- Kreutzer K, Effendy I (2014) Therapy-resistant folliculitis decalvans and lichen planopilaris successfully treated with adalimumab. *J Dtsch Dermatol Ges* 12: 74-76.
- Mihaljević N, von den Driesch P (2012) Successful use of infliximab in a patient with recalcitrant folliculitis decalvans. *J Dtsch Dermatol Ges* 10: 589-590.
- Meesters AA, Van der Veen JP, Wolkerstorfer A (2014) Long-term remission of folliculitis decalvans after treatment with the long-pulsed Nd:YAG laser. *J Dermatolog Treat* 25: 167-168.
- Castaño-Suárez E, Romero-Maté A, Arias-Palomo D (2012) Borbujo J Photodynamic therapy for the treatment of folliculitis decalvans 28(2): 102-104.
- Bastida J, Valerón-Almazán P, Santana-Molina N, Medina-Gil C, Carretero-Hernández G (2012) Treatment of folliculitis decalvans with tacrolimus ointment. *Int J Dermatol*.51: 216-220.
- Smith EP, Hardaway CA, Graham BS, Johnstone PA (2006) Folliculitis decalvans treated with radiation therapy. *Cutis* 78: 162-164.
- Parlette EC, Kroeger N, Ross EV (2004) Nd:YAG laser treatment of recalcitrant folliculitis decalvans. *Dermatol Surg* 30: 1152-1154.
- Paquet P, Piérard GE (2004) Dapsone treatment of folliculitis decalvans. *Ann Dermatol Venereol* 131: 195-197.
- Fernandez-Obregon AC (1997) Azithromycin for the treatment of acne. *Int J Dermatol* 36: 239-240.
- Innocenzi D, Skroza N, Ruggiero A, Concetta Potenza M, et al. (2008) Moderate acne vulgaris: efficacy, tolerance and compliance of oral azithromycin thrice weekly for. *Acta Dermatovenerol Croat* 16: 13-18.
- Antonio JR, Pegas JR, Cestari TF, Do Nascimento LV (2008) Azithromycin pulses in the treatment of inflammatory and pustular acne: efficacy, tolerability and safety. *J Dermatolog Treat* 19: 210-215.
- Hasibur MR, Meraj Z (2013). Mymensingh Combination of low-dose isotretinoin and pulsed oral azithromycin for maximizing efficacy of acne treatment. *Med J* 22: 42-48.
- De D, Kanwar AJ (2011) Combination of low-dose isotretinoin and pulsed oral azithromycin in the management of moderate to severe acne: a preliminary open-label, prospective, non-comparative, single-centre study. *Clin Drug Investig* 31: 599-604.
- Jung Kim S, English JC (2012) Minocycline-induced hyperpigmentation. *J Pediatr Adolesc Gynecol* 25: 77-78.
- Geria AN, Tajirian AL, Kihiczak G, Schwartz RA (2009) Minocycline-induced skin pigmentation: an update. *Acta Dermatovenerol Croat* 17: 123-6.

- 
24. Banjanac M, Munić Kos V, Nujić K, Vrančić M, Belamarić D et al. (2012) Anti-inflammatory mechanism of action of azithromycin in LPS-stimulated J774A.1 cells. *Pharmacol Res* 66: 357-362.
25. Yamauchi K, Shibata Y, Kimura T, Abe S, Inoue S, et al. (2009) Azithromycin suppresses interleukin-12p40 expression in lipopolysaccharide and interferon-gamma stimulated macrophages. *Int J Biol Sci* 5: 667-678.
26. Mizunoe T, Kadota J, Kishi T, Tokimatsu K, Hiramatsu K, et al. (2004). The mechanism of apoptosis induction in lymphocytes by macrolide antibiotics and the related intra-cellular molecular structure. *Jpn J Antibiot* 57 Suppl A: 59-61.
27. Abdel Fattah NS, Darwish YW (2013) In vitro antibiotic susceptibility patterns of *Propionibacterium acnes* isolated from acne patients: an Egyptian university hospital-based study. *J Eur Acad Dermatol Venereol* 27: 1546-1551.
28. Otberg N, Kang H, Alzolibani AA, Shapiro J (2008) Folliculitis decalvans. *Dermatologic Therapy* 21: 238-244.