

# Hair regrowth in 2 patients with recalcitrant central centrifugal cicatricial alopecia after use of topical metformin



Erinolaoluwa F. Araoye, BS,<sup>a</sup> Jamael A. L. Thomas, MPH,<sup>b</sup> and Crystal U. Aguh, MD<sup>a</sup>  
Baltimore, Maryland and Dallas, Texas

**Key words:** black hair; central centrifugal cicatricial alopecia; ethnic hair; topical therapeutics; treatment.

## INTRODUCTION

Central centrifugal cicatricial alopecia (CCCA) is a progressive scarring alopecia predominately occurring in women of African descent.<sup>1</sup> The progression of hair loss is insidious, often occurring in the absence of clinical signs of overt inflammation. As a result, end stage fibrosis occurs at a rate disproportionate to the rate of inflammation, a finding common to a class of disorders termed *fibroproliferative disorders* (FPDs).<sup>2</sup> Staging of CCCA is based on distribution, frontal (type a) or vertex (type b) location, and extent of the area of affected scalp scaled numerically from normal (0) to bald scalp (5).<sup>1</sup> Metformin, commonly used for glycemic control in type 2 diabetes, has shown efficacy in improving fibrosis in a mouse model of FPD through the mediation of adenosine monophosphate-activated protein kinase (AMPK).<sup>3</sup> We present 2 cases of hair regrowth after topical use of metformin for CCCA.

## CASE REPORTS

### Case 1

Patient 1 is a 69-year-old black woman with biopsy-confirmed stage 4a CCCA. She reported onset of hair loss in her late 50s that had progressed over time. She was previously treated with minoxidil 5% foam twice daily, 8 cycles of intralesional triamcinolone acetonide (ILK), topical clobetasol 0.05% ointment, and Viviscal (Viviscal Limited, Ewing, NJ) supplement with very minimal improvement. After 5 years of standard therapy, the patient elected to discontinue ILK and topical minoxidil. She was started on topical 10% metformin cream, initially at a frequency of 3 times per week and later increased

### Abbreviations used:

CCCA:	central centrifugal cicatricial alopecia
FPD:	fibroproliferative disorder
AMPK:	adenosine monophosphate-activated protein kinase
ILK:	intralesional triamcinolone acetonide

to once daily. Substantial regrowth was noted after 6 months (Fig 1).

### Case 2

Patient 2 is a 54-year-old black woman with stage 4a CCCA who first noticed hair loss in her early 40s. She was treated with a combination of ILK (completed 5 cycles), minoxidil 5% foam, topical ketoconazole 2% cream, and clobetasol 0.05% ointment for 9 months at Johns Hopkins Hospital with marginal improvement. The patient elected to continue minoxidil and ILK with the addition of topical 10% metformin cream once daily as an adjunct therapy. Notable improvement was observed after 4 months of adding topical metformin (Fig 2).

## DISCUSSION

CCCA is a condition for which few effective treatment options exist. Current standard therapies aim at reducing inflammation; however, unlike other forms of primary cicatricial alopecia, such as lichen planopilaris and discoid lupus, that are characterized by overt inflammation, fibrosis is the dominant response in CCCA. This is reminiscent of FPDs, such as uterine fibroids, systemic sclerosis, and

From the Department of Dermatology, Johns Hopkins School of Medicine, Baltimore<sup>a</sup>; and the School of Medicine, University of Texas Southwestern Medical Center, Dallas.<sup>b</sup>

Funding sources: None.

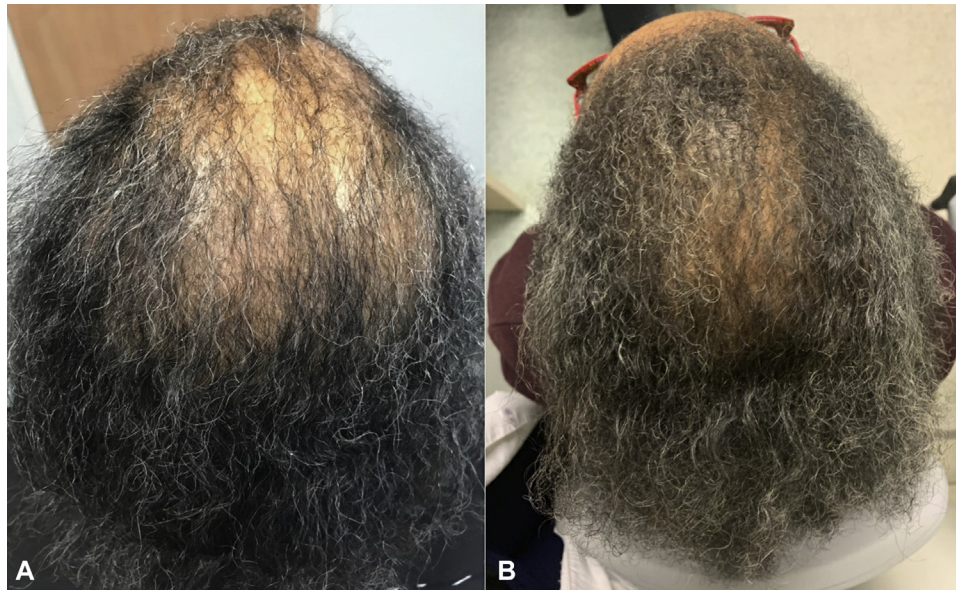
Conflicts of interest: None disclosed.

Correspondence to: Crystal U. Aguh, MD, JHOC 8th Fl, 601 N Caroline St, Baltimore, MD 21231. E-mail: [cag1@jhmi.edu](mailto:cag1@jhmi.edu).

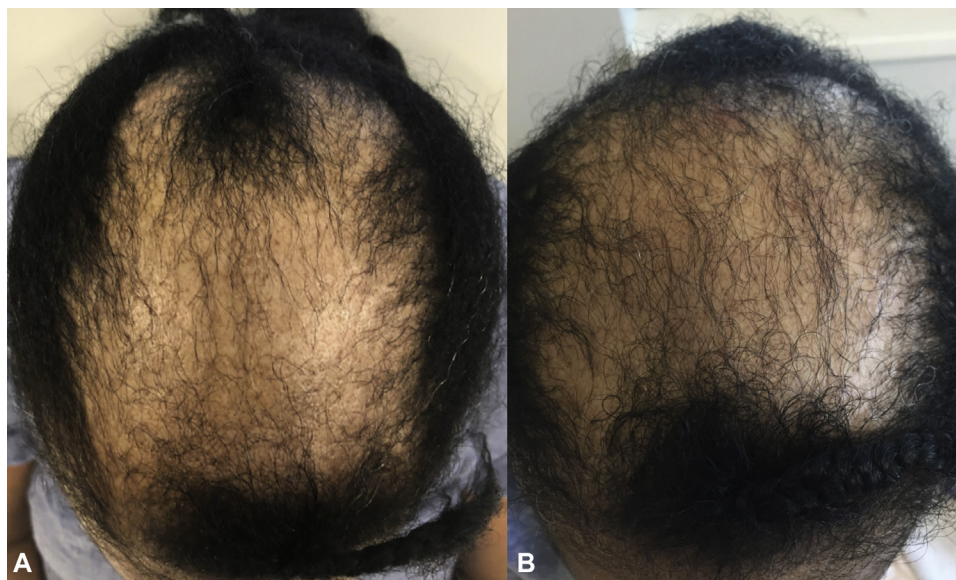JAAD Case Reports 2020;6:106-8.  
2352-5126

© 2019 by the American Academy of Dermatology, Inc. Published by Elsevier, Inc. This is an open access article under the CC BY-NC-ND license (<http://creativecommons.org/licenses/by-nc-nd/4.0/>).

<https://doi.org/10.1016/j.jidcr.2019.12.008>



**Fig 1.** Improvement of central centrifugal cicatricial alopecia after application of topical metformin in case 1. **A**, Central centrifugal cicatricial alopecia in patient 1 before initiation of topical metformin. **B**, Hair regrowth observed after 6 months of topical 10% metformin treatment.



**Fig 2.** Improvement of central centrifugal cicatricial alopecia after application of topical metformin in case 2. **A**, Central centrifugal cicatricial alopecia in patient 2 before initiation of topical metformin. **B**, Hair regrowth after 4 months of topical 10% metformin treatment.

keloids. We previously published results that showed a 5-fold increase in the occurrence of uterine fibroids in women with CCCA compared with age-, race-, and sex-matched control individuals.<sup>4</sup> Furthermore, research has shown preferential expression of fibroproliferative genes in patients with CCCA. In a microarray study, *PRKAA2*, a gene that encodes for AMPK, was found to be

underexpressed by one third in CCCA scalp samples.<sup>5</sup> Reduced activity of AMPK is implicated in the pathogenesis of hepatic fibrosis and idiopathic pulmonary fibrosis.<sup>3,6</sup>

Metformin primarily exerts its effect through AMPK activation and has a range of downstream hormonal effects that include improvement of insulin sensitivity through increased glucose uptake and

reduction of circulating lipids and androgens.<sup>7,8</sup> Androgens are known to promote conversion of terminal hairs to vellus hairs; hence, medicines that reduce circulating androgens, such as metformin, could alter the progression of androgenetic alopecia.<sup>9</sup> In a mouse model of idiopathic pulmonary fibrosis, metformin reversed and accelerated resolution of the fibrotic process via deactivation and apoptosis of myofibroblasts.<sup>3</sup> Therefore, there might be a role for metformin in CCCA.

Our 2 patients experienced visible hair regrowth when metformin 10% compounded in Lipoderm (PCCA, Houston, TX), a cream that optimizes transcutaneous absorption, was applied topically. Neither experienced a telogen effluvium preceding hair regrowth. The conversion of vellus follicles to terminal follicles is important for hair regrowth; however, this was not assessed with trichoscopy. Adverse effects of systemic metformin include gastrointestinal symptoms such as nausea, bloating, diarrhea, decreased appetite, and, rarely, lactic acidosis and hypoglycemia. Neither patient was taking oral metformin. No systemic adverse effects were reported with topical use. Patients experienced scalp dryness and irritation, which improved with use of a topical moisturizer or emollient. The dose of metformin, 10%, was chosen based on recommendations from pharmacists with the goal of minimizing systemic absorption while maintaining a therapeutic effect. There is potential for increasing the dose if the patient responds to and tolerates the topical therapy. Future studies will aim to quantify the vellus-to-terminal hair ratio by using trichoscopy to

understand the potential for sustained improvement. Large randomized controlled studies are needed to fully understand the potential benefit of topical metformin use in CCCA. We encourage further study of its use in patients with advanced CCCA who have not responded to standard therapies.

#### REFERENCES

1. Olsen EA, Callender V, Sperling L, et al. Central scalp alopecia photographic scale in African American women. *Dermatol Ther.* 2008;21(4):264-267.
2. Wynn TA. Common and unique mechanisms regulate fibrosis in various fibroproliferative diseases. *J Clin Invest.* 2007;117(3):524-529.
3. Rangarajan S, Bone NB, Zmijewska AA, et al. Metformin reverses established lung fibrosis in a bleomycin model. *Nat Med.* 2018;24(8):1121-1127.
4. Dina Y, Okoye GA, Aguh C. Association of uterine leiomyomas with central centrifugal cicatricial alopecia. *JAMA Dermatol.* 2018;154(2):213-214.
5. Aguh C, Dina Y, Talbot CC, Garza L. Fibroproliferative genes are preferentially expressed in central centrifugal cicatricial alopecia. *J Am Acad Dermatol.* 2018;79(5):904-912.e1.
6. Da Silva Morais A, Abarca-Quinones J, Guigas B, et al. Development of hepatic fibrosis occurs normally in AMPK-deficient mice. *Clin Sci.* 2009;118(6):411-420.
7. An H, He L. Current understanding of metformin effect on the control of hyperglycemia in diabetes. *J Endocrinol.* 2016;228(3):R97-R106.
8. Markowicz-Piasecka M, Huttunen KM, Mateusiak L, Mikiciuk-Olasik E, Sikora J. Is metformin a perfect drug? Updates in pharmacokinetics and pharmacodynamics. *Curr Pharm Des.* 2017;23(17):2532-2550.
9. González-Saldivar G, Rodríguez-Gutiérrez R, Ocampo-Candiani J, González-González JG, Gómez-Flores M. Skin manifestations of insulin resistance: From a biochemical stance to a clinical diagnosis and management. *Dermatol Ther (Heidelb).* 2016;7(1):37-51.